NEURO-HISTOLOGICAL EFFECTS OF ZINC DEFICIENT DIET ON THE OLFACTORY BULB OF ADULT ALBINO RAT

Dr S M DAWAR HUSAIN

Department of Anatomy, J N. Medical College, AMU ***Aligarh-202002***

ABSTRACT

Zinc is amongst some of the trace elements which are essential for many metabolic functions in the biological system. This investigation was conducted to explore effects of ZN++ deficiency on the olfactory bulb of albino rats to have an idea about it's corresponding effect on human beings. 8 Charles foster strain-rats were kept for 30 days with half the number of rats on stock ration diet and other half the number of rats i.e. 4 on Zn++ deficient diet. Then olfactory bulb sections were obtained by standard methods after sacrificing the rats. The sections were stained by H & E, Thionine and Glees silver stains. On microscopic observations some layers of olfactory bulb showed degenerative changes.

INTRODUCTION

Zinc is required for DNA, RNA and protein synthesis (Sand stead et al. 1969), cell division (Taylor, *et al.* 1982) and gene expression and (Miller, *et al.* 1985 and Kluge, and Rhoden 1987) for activity of many enzymes. Anencephaly and hydrocephaly have been reported following 'in utero' zinc deficiency in rats (Dreosti, andSmoth 1983).Zn^{++}belongs the group HB transitional elements and occupies D-block of the periodic table. Long term Cd++ administration results in increase amount of Zn^{++} associated with metallothionein (Keun Chung, *et al.* 1988) resulting into a deficiency of available Zn^{++} in the body.

Since no experimental studies were available regarding histological changes in the olfactory bulb of albino rats secondaryto Zn^{++} deficiency states, the aim of this study is to possibly fill the lacuna in the knowledge of this subject.

MATERIAL AND METHOD

Animal

8 Charles' foster strain"rats, 4 males& 4 females were taken. Rats were divided in to group A &groupBwitheach group containing 4 rats. Group A rats were kept on stock ration diet and tap water while group B rats were kept on Zn deficient diet and double distilled water.

Rats were individually housed in plastic cages. Rats were weighed on alternate days. 15 gm food was given to each group daily. Group B rats received Zn^{++} deficient diet. After 30 days rats weresacrificed. Intra venous infusion set was used as perfusion apparatus. 10% formlin

solution in normal saline was used as perfusion fluid. In perfusion fixation, rats were anaesthetized by intra peritoneal injectino of nembutol 35 mg/kg body weight. Than thorax of rats was opened. Next 18 gauge needle introduced into ascending aorta through Lt ventricle. Than Rt. Atrium was widely opened and perfusion was done by formal saline at pressure of 5 feet of water pressure. Perfusion was stopped when head & tail stiffness was pronounced and there was oozing of perfusion fluid on cutting the snout with the scissors. Than brain was quickly removed.Next olfactory bulbs were cut and put in a fixative (formal saline) overnight. Then after usual procedures, sections were cut at 10 thickness. Staining was done by haematoxylin and eosin, thionine and glees silver stains.

OBSERVATION AND RESULTS

Fig.1..Photomicrograph of the olfactory bulb of an albino rat on normal diet,.Thionine x 200.

Sections of olfactory bulb in this group of rats showed the following features

(a) Lamina fibrosa; this is olfactory nerve fibre layer showing unmyelinatedfibres running in various directions, forming a closed network. At some places these fibres were seen to penetrate the olfactory glomeruli

(b) Lamina glomerulosa clear, round or oval regions (olfactory glomeruli) made up of unmyelinatedfibres, surrounded by small sized periglomerular cells. Somesmall cells were also found scattered amongst the fibreswwithin the olfactory glomeruli.

(c) Outer plexiform layer: Wider and clear zone of unmeilinaied nerve fibres; widely scattered small mediu.m and even some large sized cells were seen. Large size cells were like mitral cells, some radially arranged nerve fibres were also seen.

(d) Mitral cell layer, A few cell thick thin layer of darkly staining large sized oval or elongated mitral cells with long axis lying in a radial direction.

(e) The granular layer, thicker zone poorly demarcated from the mitral layer, containing small size granular cells, medium size neurons were also seen.'

(f) Inner plexiform layer, seen as lighter zone apparently made up of unmyelinated nerve fibres, small sized stellate neurons were also seen,

(g) The subependymal layer, Appeared as darkly stained zone in the centre of the olafactory bulb, the cells were in the form of a dense collection of fine, sand like small sized cells.

Fig.2a : Photomicrograph of olfactory bulb of an albino rat on zinc deficient diet. Thionine x 150.

Sections of olfactory buib showed degenerative changes in lamina fibrosa layer (as loosened unmyelinated nerve fibres), lamina glomerulosa showed flattening and distortion of glomeruli over certain regions. The periglomerular cells showed degeneration at some places, granular layer showed clumping and degeneration of many medinm sized cells. Cells and fibres in other layers appear to be unaffected.

Fig.2b : Photomicrograph of the olfactory bulb of an albino rat on zinc deficent diet. Thionine X 400.

More conspicuous picture of degenerativechanges in various layers as noted in Fig. 2a, with clumping and degeneration of many medium sized cels in the granular layer

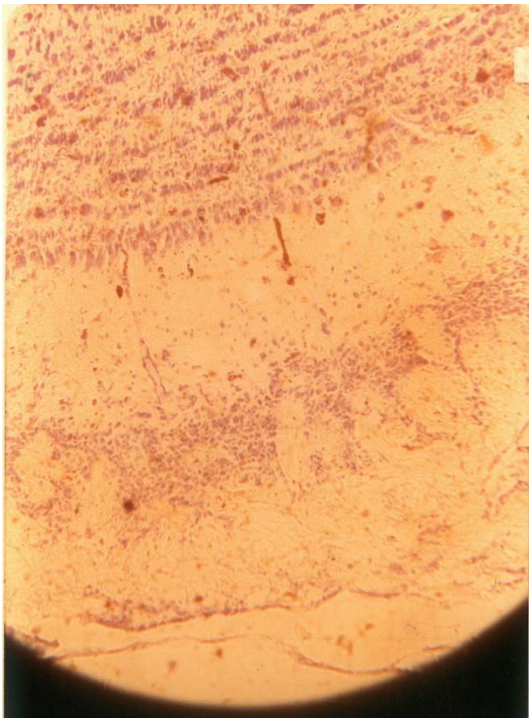

Fig.1. Photomicrograph of the olfactory bulb of an albino rat on normal diet. Thionine x 200

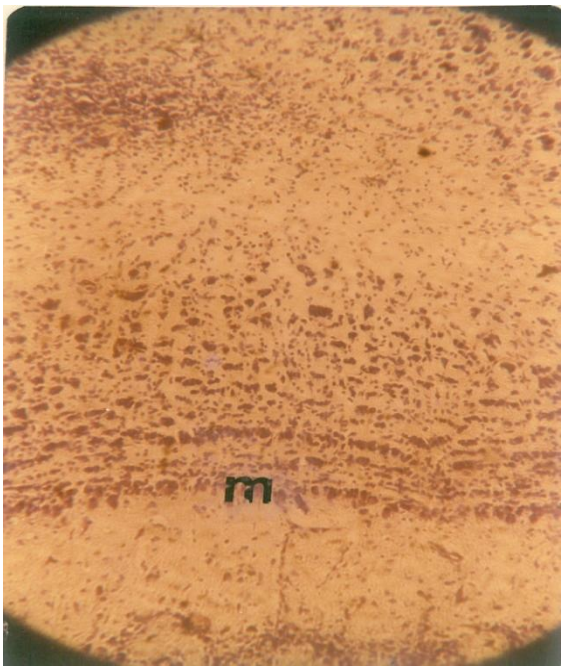

Fig. 2a : Photomicrograph of the ola factory bulb of an albino on zinc deficient diet. Thionine x 150

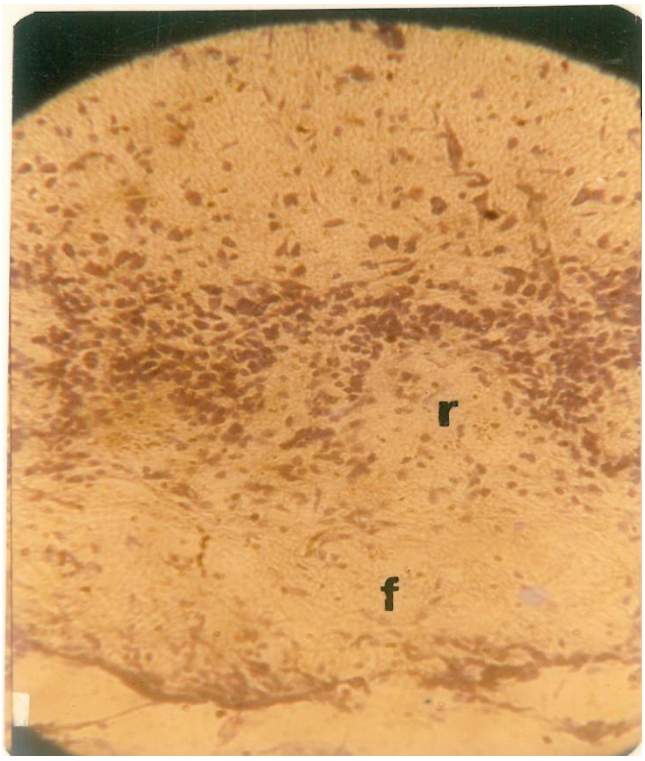

Fig. 2b: Photomicrograph of the olfactory bulb of an albino on zinc deficient diet. Thionine x 400.

DISCUSSION

No study regarding histological changes in the olfactory bulb of albino rats following Zn^{++} deficiency has been reported.

Zn^{++}deficien.y may result from Cd^{++} administration (Keun***et al.*** 1988).

Microscopic findings of structural alterations in the olfactoiy bulb following Zn^{++} deficiency of albino rats; sections of the olfactory bulb showed degenerative changes in lamina fibrosa layer (as loosened unmyelinated nerve fibres), lamina glomerulosa showed flattening and distortion of glomeruli over certain regions. The periglomerular cells showed degeneration at some places, granular layer showed clumping and degeneration of many medium sized cells. Cells and fibres in other layers appeared to be unaffected.

REFERENCES.

- Dreosti, I.E., Smith R.M (eds) 1983 ***''Neurobiology of the Trace Elements",***Clifton N.J., Humana Press.. .
- Keun Chung, Nadia Remero, Don Tinker, Card L.L. Keen, KenjieAmermiye and Robert Rucher 1988 Rate of copper in the regulation and accumulation of superoxide dismutase and metallothionein in rat liver ***'.Journal of Nutrition, III)*** : 859-864.
- Kluge A., and Rhoden, A. 1987."Zinc Finger'" A novel protein motilforNucleic Acid Recognition. ***Trends Bio Chemical Science, 12*** : 461-469.
- Miller, **J.,** McLachlamA.D.JandKlug 1985 Repretitive zinc-binding domains in the protein transcription factor III-A for xenopus oocytes ***Embryology : 4:*** 1609-14
- Saiidstead, H.H. and Rinaldi; R.A.1969 Impairment of deoxyribonucleic acid synthesis by dietary zinc deficiency in the rat. ***Journal of Cell Physiology, 73,*** 81-84.
- Taylor, M.C., Demayo, A. and Taylor, K.W. 1982 Effects of zinc on humans, laboratory and farm animals, terrestrial plants, and freshwater aguatic life. *CPC Critical Reviews in Environmental Control,* ***12,*** 113-181